

Successful Mannitol Treatment in Young Man Patient with Spontaneous Operable Chronic Subdural Hematoma: A Case Report

Kharisma Ridho Husodo¹, Akhmad Suryonurafif^{2*}, Rahmi Andriani³

¹ General Practitioner, Yogyakarta Islamic Hospital PDHI (Persaudaraan Djama'ah Haji Indonesia), Yogyakarta.

² Neurosurgeon, Yogyakarta Islamic Hospital PDHI (Persaudaraan Djama'ah Haji Indonesia), Yogyakarta.

³ Neurologist, Yogyakarta Islamic Hospital PDHI (Persaudaraan Djama'ah Haji Indonesia), Yogyakarta.

DOI: 10.29303/jku.v12i4.907

Article Info

Received : October 5, 2023

Revised : November 1, 2023

Accepted : November 1, 2023

Abstract: Chronic subdural hematoma (cSDH) is a common neurosurgery disorder among the elderly, but it is rare in the younger patients. Incidence of cSDH is approximately 5/100.000 a year in the general population but it has higher rate in elderly. Most cases of cSDH has prior trauma event which then leads to hematoma formation in subdural space and inflammation is believed to have an important role in its pathophysiology. This study reports a spontaneous cSDH case in a young adult patient whose symptoms appeared to be chronic headache, nausea, vomiting and dizziness. Any neurological deficit was absent. This patient was treated conservatively using an osmotic agent, mannitol, despite the fact that the current patient had an indication of surgical treatment. The patient was discharged from the hospital with a good outcome. After 2 months of follow-up, there was no sign of recurrence. Our study found several considerations in deciding treatment options for cSDH, including the condition of the patient and the doctor in charge's viewpoint.

Keywords: chronic subdural hematoma, conservative treatment, young patient, neurosurgery, neurology.

Citation Husodo, K. R., Suryonurafif, A., & Andriani, R. (2023). Successful Mannitol Treatment in Young Man Patient with Spontaneous Operable Chronic Subdural Hematoma: A Case Report. *Jurnal Kedokteran Unram*, 12(4), 328-331, DOI: <https://doi.org/10.29303/jku.v12i4.907>

Introduction

One of disorders in neurology and neurosurgery, named Chronic Subdural Hematoma (cSDH), is a common disease in the elderly and rarely in the young patient¹. A cSDH patient occurs collection of blood, fluid and blood degradation product which are encapsulated and layered between the dura mater and the arachnoid in the brain¹. The major cause of cSDH is believed due to traumatic events. In Asia, the incidence of cSDH is about 1-5.3 cases per 100, 000 population every year. In the elderly, the incidence of cSDH is increasing which may be associated with some medical conditions such as hemodialysis, anticoagulant, and/or antiplatelet therapy².

The clinical presentation of cSDH is broad and unspecific which makes it difficult to diagnose by signs

and symptoms. The clinical manifestation of this disease varies from no symptoms to severe symptoms such as headache, seizures, decreased memory, difficulty in speaking and swallowing, hemiplegia, walking trouble and confusion². Moreover, in young patients, cSDH suspicious is more likely to be missed due to the rare percentage of cases in group age. Clinicians rarely recommend imaging examinations such as head computed tomography (CT) scans, in patients younger than 40³.

Most cases of cSDH is managed by surgical treatment by neurosurgeons. This disease has a good prognosis usually after surgery⁴. In this paper, we reported a young adult patient with spontaneous chronic subdural hematoma treated conservatively and had a good outcome.

Email: kharisma48ridho@gmail.com

Case Report

A 24-year-old young man with a chief complaint of headache was admitted to the emergency room (ER) of Yogyakarta Islamic Hospital PDHI. The pain in the head was felt by the patient since a month ago but it was relieved using a painkiller drug from the drugstore. The characteristics of the headache was right unilateral and throbbing which worsened three days before hospital admission. The pain score was assessed using the Numerical Rating Scale with result 7. The patient also complained of dizziness, nausea and vomiting since a day ago. The patient denied any head trauma history. History of bleeding abnormality, alcohol consumption and routine drug were denied. Other neurological deficit signs and symptoms were denied.

The physical and neurological examination was within normal limits. The vital sign of the patient was normal with blood pressure was 111/64mmHg, pulse rate was 73 beats per minute, respiratory rate was 18 beats per minute, oxygen saturation was 99% without oxygen supplementation and axial temperature was 36,5⁰ celsius. A laboratory test was performed with the normal result except chloride level (Table 1.). Non-contrast CT scan was carried out at admission with result acute on chronic subdural hematoma (crescent-shaped) with trabecular type at right fronto-temporo-parieto-occipitalis, presence of midline shift to the left about 10mm, and arachnoid cyst at right temporal (Fig 1 (a)). The radiology x-ray of the chest was within normal limits.

Table 1. Laboratory study of the patient

Examination	Result	Normal Range
Hemoglobin	14,9 g/dL	12,0 - 16,0
Hematocryte	45,5 vol%	40,0 - 54,0
Leucocyte	8,42x10 ³ /uL	4 - 11 x 10 ³
Thrombocyte	241x10 ³ /uL	150 - 450 x 10 ³
Etyrocyte	5,22 x 10 ⁶ uL	4,0 - 5,5
MCV	87,2 fL	80 -100
MCH	28,6 pg	27,0 - 34,0
MCHC	32,8 g/dL	32,0 - 36,0
Neutrophil%	63,6%	50 - 70
Basophil%	0,2%	0,0 - 1,0
Eosinophil%	6,8%	0,5 - 5,0
Lymphocyte%	24,3%	20 - 40
Monocyte%	5,1%	3,0 - 12,0
Random Blood Glucose	95 mg/dL	74 - 180
Sodium	136,5 mmol/L	135 - 146
Potassium	3,97 mmol/L	3,4 - 5,4
Chloride*	101,2 mmol/L	95 - 100
Ureum	17,52 mg/dL	10,0 - 50,0
Creatinine	0,76 mg/dL	0,6 - 1,1

* Abnormal result

From first examination, the general practitioner consulted to neurologist. The patient was decided to treat conservatively using medication. The patient was given mannitol 20% 125ml intravenous every 6 hours with a tapering-off regimen. Analgesia was administered using metamizole 1gr intravenous every 8 hours. Other drugs used to treat the patient were ranitidine intravenous, ondansetron intravenous, eperisone oral, flunarizine oral. On day 6 of hospitalization, there was an improvement of the signs and symptoms of the patient. The patient felt better than he felt at admission. The neurologist planned to discharge the patient on the next day. The patient was treated for 7 days totally in the ward and during treatment, the patient's condition was getting better day by day and there was no sign of worsening so the doctor in charge did not consult to a neurosurgeon.

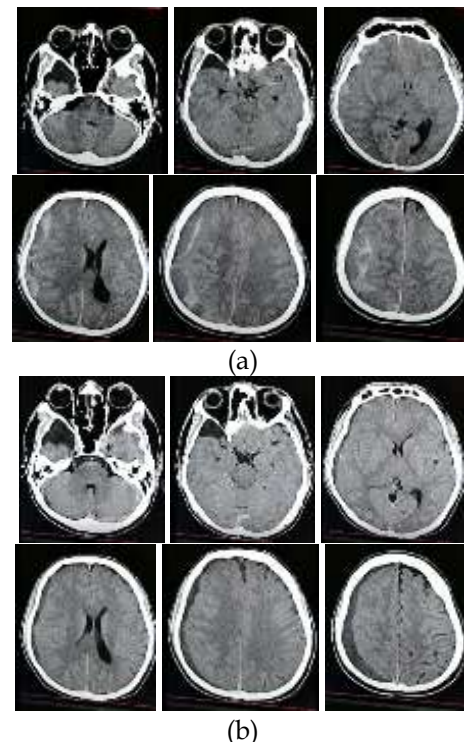


Figure 1. Non-Contrast Head CT-scan of patient (a) First admission at the ER. (b) Evaluation at the outpatient clinic

The patient was admitted to the outpatient clinic on the 6 days after discharge. The patient complained of neck stiffness, but headache and dizziness were absent. Then he was given symptomatic medications. The next visit was ten days after, the patient still had the same complaint. In the third visit, the complaint of the patient was persistent then non-contrast CT scan was performed with result chronic subdural hematoma with homogenous type at the right fronto-parietal region and the hematoma volume was smaller compared to the first

CT-scan. The midline shift was also improved than before. The arachnoid cyst was persistent at the right temporalis. The patient was referred internally to the neurosurgeon outpatient clinic. Neurosurgeon examined the patient and decided to do not any planned surgery due to the improvement of signs and symptoms of the patient.

Discussion

The comparison incidences of cSDH between over 60 years of age and under 60 years of age is 17 : 1 ratio². Most cases of cSDH is caused by prior trauma event which makes a tear to bridging veins. The progression of the disease after trauma is accumulations of blood, fluid or blood products degradation in subdural space. Due to the chronic process, about 4 to 7 weeks, the patient develops signs and symptoms when the accumulated hematoma from small bleeding is enough to generate brain space-occupying effect⁵. Another theory stated that inflammation has a key role in the pathophysiology of cSDH. It is supported by the histological findings that the dura is lined with a modified connective tissue cells layer in cSDH. These cells can phagocyte and develop into fibro-cellular connective tissue, allowing the formation of neo membranes as seen in cSDH. Neo-membrane formation is a result of clot fibrinolysis, production of granulation tissue, and release of angiogenic factor. This neo-membrane has immature, fragile and leaky blood vessels which are prone to microbleeding⁷. Both neo-membrane and chronic inflammatory processes induce hematoma enlargement and delay blood clot².

Head CT scans has advantages due to faster examination¹. In cSDH patients, this imaging reveals a crescent-shaped of hematoma which it density ranging from hypodense to isodense indicating the chronic time. The hyperdense features may be present in acute on chronic SDH as like as in this case report. Indication of surgery in cSDH is if the hematoma has a thickness $\geq 10\text{mm}$ and/or midline shift $\geq 5\text{mm}$. It is also indicated if subacute or chronic subdural of any thickness causing mass effect or neurologic signs and symptoms is present². There are four type lesions in cSDH as shown in figure 2. The size and type of lesion determine the decision of the neurosurgeon to choose treatment options².

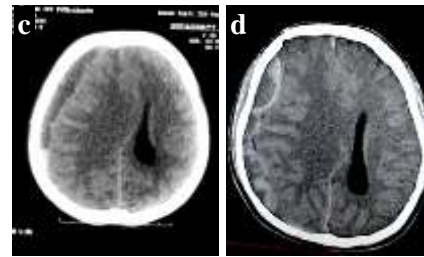
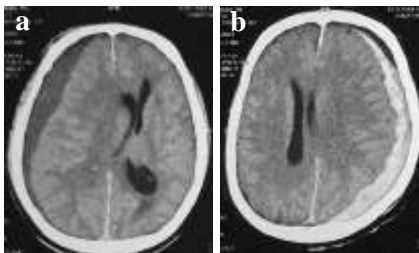


Figure 2. Lesion type of cSDH (a) Homogenous. (b) Laminar. (c) Separated. (d) Trabecular.

Based on the type of cSDH lesion, Kwon *et al* analyzed that recurrence rates were highest in the separated type with a number 31%. The reported recurrence rates in the homogeneous, laminar and trabecular types were 9 %, 12,5% and 5,1% respectively. The recurrence rates were affected by the role of the pro-inflammatory cytokines. In the separated hematoma type, the concentration of pro-inflammatory cytokines was the highest, which correlated with a greater tendency of re-bleeding. Therefore, if the situation permits, surgery in the homogeneous and trabecular stages may reduce the recurrence rate⁸.

Eventually, the patient was treated with conservative treatment using mannitol to deal with increased intracranial pressure. An osmotic agent like mannitol is a drug to reduce brain volume thus the compression of the brain will decrease^{1,2}. Mannitol acts by increasing the tonicity of plasma then it draws water out of the brain parenchyma into intravascular space. But osmotic therapy is not effective to treat for hematoma absorption¹⁰. A study reported by Guo *et al* showed that the osmotic agent, mannitol, with additional dexamethasone treatment had a positive effect to improve brain swelling and decrease intracranial pressure in cSDH patients. Moreover, mannitol is usually maintained for no more than 5 days to avoid side effects such as fluid and electrolyte imbalance, pulmonary edema, and renal failure. In the current case, the mannitol was reduced stepwise during treatment to allow neurofunction rehabilitation⁹.

The steroid drug was not given in the current case. Dexamethasone acts by inhibiting the aggregation of immune inflammatory cells, phagocytosis, and release of inflammatory mediators. In neurosurgery cases, steroids can be used to as analgesia or assist symptomatic treatment. In cSDH patients, leukocytes level is not high but many immune inflammatory cells, inflammatory factors, and other inflammatory reaction products are present in the hematoma wall and cavity of cSDH⁹.

Nakao *et al* research stated that patients with asymptomatic or mildly symptomatic cSDH are managed conservatively with 20.8% to 50% will have spontaneous regression. They assessed that conservative

treatment should aim to reduce hematoma to avoid surgical intervention¹⁰. On the other hand, a study conducted by Kostas *et al* showed that cSDH patients had worse outcomes in conservative treatment group, while patients treated with surgery with or without corticosteroids had better outcomes⁶. Thus, the treatment options for cSDH depend on the patients' condition and the doctor's point of view.

Conclusion

Some young adult patients with persistent headache may have cSDH, thus clinicians should consider to perform Head CT scan. Most cases of cSDH must be treated with surgical procedures because it is documented that surgical treatment has better outcomes. Nevertheless, treatment choice depends on the patient's condition and the doctor's point of view.

Acknowledgements

The authors would like to thank the patient for giving consent to participate in this case report. We also gratefully acknowledge the support of Yogyakarta Islamic Hospital PDHI in helping with the patient data completion.

Conflicts of Interest

There was no any conflict of interest in this case report.

Funding

Not applicable.

References

- [1] Edlmann, E., Giorgi-Coll, S., Whitfield, P.C., Carpenter, K.L.H., Hutchinson, P.J. 2017. Pathophysiology of chronic subdural haematoma: inflammation, angiogenesis and implications for pharmacotherapy. *J Neuroinflammation* 14, 108 (2017). <https://doi.org/10.1186/s12974-017-0881-y>
- [2] Yadav, Y. R., Parihar, V., Namdev, H., & Bajaj, J. 2016. Chronic subdural hematoma. *Asian journal of neurosurgery*, 11(4), 330-342. <https://doi.org/10.4103/1793-5482.145102>
- [3] Won, Y.D., Yi, H.J., Lee, Y.J., Chun, H.J., Cho, H., Bak, K.H. 2013. Chronic Subdural Hematoma in Young Adult : An Age Comparison Study. *Korean J Neurotrauma* 2013;9:6-11
- [4] Salazar, L.R.M., Miranda, H.R.A., Miranda, W.C., Cerra, G.A., Runiano, A.M. 2014. Spontaneous chronic subdural hematoma in a young male patient: case report. *Romanian Neurosurgery* (2014) XXI 2: 239 - 244
- [5] Skovrlj, B., Rasouli, J., Levy, A.S., Raksin, P.B., Ulman, J.S. 2015. *Chronic Subdural Hematomas*. In : J. S. Ulman & P. B. Raksin, Ed. *Atlas of Emergency Neurosurgery*. New York: Thieme, pp. 16 - 32
- [6] Nakao J, Marushima A, Fujita K, Fujimori H, Mashiko R, Kamezaki T, Sato N, Shibata Y, Takano S, Ishikawa E. 2023. Conservative Treatment of Chronic Subdural Hematoma with Gorei-san. *Neurol Med Chir (Tokyo)*, 15;63(1):31-36. doi: 10.2176/jns-nmc.2022-0229.
- [7] Nouri, A., Gondar, R., Schaller, K., Meling, T. 2021. Chronic Subdural Hematoma (cSDH): A review of the current state of the art. *Brain and Spine*, Volume 1, 2021, 100300
- [8] Kwon, S.M., Lee, M.H., Seo, Y., Kim, Y.I., Oh, H.J., Kim, K.H., Choi, K.S., Chong, K. 2022. A Radiological Assessment of Chronic Subdural Hematomas. *Korean J Neurotrauma*, Vol 18(1) : 12 - 21. doi : 10.13004/kjnt.2022.18.e24
- [9] Guo, Z., Sun, L., Dong, Q., Liu, C., Zhou, R., Gong, S., Wang, G. 2015. A case report of successful conservative treatment for huge acute traumatic intracerebral hematoma. *Medicine (Baltimore)*. Apr; 94 (15):e656. doi: 10.1097/MD.0000000000000656. PMID: 25881839; PMCID: PMC4602508.
- [10] Kostas,F., Polikceni, K., Vasilios, P., George, F. 2019. The outcome after surgical vs nonsurgical treatment of chronic subdural hematoma with dexamethasone. *Interdisciplinary Neurosurgery Volume* 16, June 2019, Pages 70-74